



Transworld Research Network  
37/661 (2), Fort P.O.  
Trivandrum-695 023  
Kerala, India

Cytoreductive Surgery in Gynecologic Oncology: A Multidisciplinary Approach, 2010: 13-34  
ISBN: 978-81-7895-484-4 Editor: Yusuf Yildirim

## 2. Surgical anatomy of upper abdominal solid organs for gynecologic oncologists

Yusuf Yildirim and Emre Gultekin

*Aegean Obstetrics & Gynecology Education and Research Hospital, Department of Gynecologic Oncology, Gaziler Cad., No 468, Yenisehir, Izmir, Turkey*

**Abstract.** In ovarian cancer standard treatment is cytoreductive surgery followed by platinum-based chemotherapy and residual disease after surgery is generally considered the most important modifiable prognostic factor. Cytoreductive surgery can also be performed for other gynecologic malignancies especially endometrial cancer. Nowadays, in parallel with increasing experiences and developing medical/surgical techniques, gynecologic oncologists have recently performed cytoreductive surgery with increasing frequencies. Performing cytoreductive surgery for any type of advanced abdominal malignancy is required a comprehensive knowledge about multivisceral organ resections including gastrointestinal resections, diaphragm peritonectomy and/or resection, splenectomy, distal pancreatectomy, liver resection, and adrenal/renal resections. Anyone who performs these procedures should have adequate knowledge about surgical anatomy of intraabdominal organs. This chapter presents basic knowledge about surgical anatomy of upper abdominal solid organs for clinicians dealing with gynecologic cancer surgery.

### Introduction

Numerous studies have documented that extensive cytoreductive surgery followed by platinum-based combination chemotherapy is a cornerstone

Correspondence/Reprint request: Dr. Yusuf Yildirim, Aegean Obstetrics & Gynecology Education and Research Hospital, Department of Gynecologic Oncology, Gaziler Cad., No 468, Yenisehir, Izmir, Turkey  
E-mail: dr.yusufyildirim2@yahoo.com.tr

approach and optimal cytoreduction ( $\leq 1$  cm residual disease volume) is associated with long-term survival in patients with advanced (FIGO stage III and IV) ovarian cancer. Survival effect of primary maximal/optimal cytoreductive surgery has clearly been established (1-12). Among the well known prognostic factors in ovarian cancer, only amount of residual disease can be influenced by the surgeon and the amount of residual disease after surgery is generally considered the most important modifiable prognostic factor. However, the ability to successfully perform optimal cytoreduction ranges from 20% to 90% (3-10). Many institutions have recently begun to perform aggressive/ultra-radical procedures to increase their optimal cytoreduction rates. Diaphragm peritonectomy and/or resection, splenectomy, distal pancreatectomy, liver resection, and adrenal/renal resections are among the procedures reported to be both feasible and associated with acceptable morbidity for cytoreduction of ovarian cancer (10, 13-33).

In ovarian carcinoma, not only primary cytoreductive surgery but also secondary cytoreductive surgery in the selected cases (e.g., patients with low-volume disease and a long-term disease-free interval) may improve survival. As with primary cytoreductive surgery, the optimal resection rates obtained with secondary cytoreductive surgery vary depending on the centers with the reported rates ranging from 29% to 87% (Table 1).

**Table 1.** Published results on optimal cytoreduction rates during secondary surgery and factors influencing survival after secondary cytoreduction.

Reference	n	% optimally cytoreduced	Factors influencing survival after secondary surgery
Berek (1983) (34)	21	29%	RDV-S (p<0.01)
Segna (1993) (35)	100	61%	RDV-S (p=0.0001)
Gadducci (2000) (36)	30	83%	RDV-S (p=0.04)
Eisenkop (2000) (37)	106	85%	RDV-S (p=0.0007)
Gungor (2005) (38)	44	77%	RDV-S (p=0.007)
Pfisterer (2006) (39)	267	76%	RDV-S (p<0.0001)
Ayhan (2006) (40)	64	83%	RDV-S (p=0.004)
Benedetti Panici (2007) (41)	47	87%	RDV-S (p=0.02), CA-125 (p=0.034)
Salani (2007) (42)	55	74.5%	RDV-S (p<0.01), DRI (p<0.01), NRCS (p<0.03)
Tebes (2007) (43)	85	86%	DFI (p<0.01), RDV-P (p<0.02), RDV-S (p<0.05)
Bae (2009) (44)	54	87%	PFS (p=0.043), Site of recurrence (p=0.013)
Cheng (2009) (45)	21	67%	No effect of RDV-S (p>0.05)*

RDV-S=residual disease volume after secondary surgery, RDV-P=residual disease volume after primary surgery, DRI=diagnosis-to-recurrence interval, NRCS=number of radiographic recurrence sites, DFI=disease-free interval before secondary surgery, PFS=progression-free survival before secondary surgery, \*: There was no significant statistical difference in median survival between patients with optimal and suboptimal secondary surgical cytoreduction, with an estimated survival of 10 months and 9.8 months, respectively (P>0.05).

In recent years, cytoreductive surgery including the resection of upper abdominal organs has been increasingly used in endometrial cancers as well as other primary and secondary gynecologic malignancies in addition to ovarian carcinoma (46-49). In parallel with this, gynecologic oncologists have recently performed upper abdominal surgery with increasing frequencies. Therefore, the clinicians practicing gynecologic cancer surgery, especially ovarian carcinoma surgery, should have sufficient knowledge about the surgery of upper abdominal organs. Such an improvement in knowledge makes the gynecologic oncologic surgeons more enthusiastic for optimal cytoreduction, which is associated with improved survival. This chapter presents basic knowledge about surgical anatomy of upper abdominal solid organs for gynecological oncologists.

## **Surgical anatomy of the liver (50-62)**

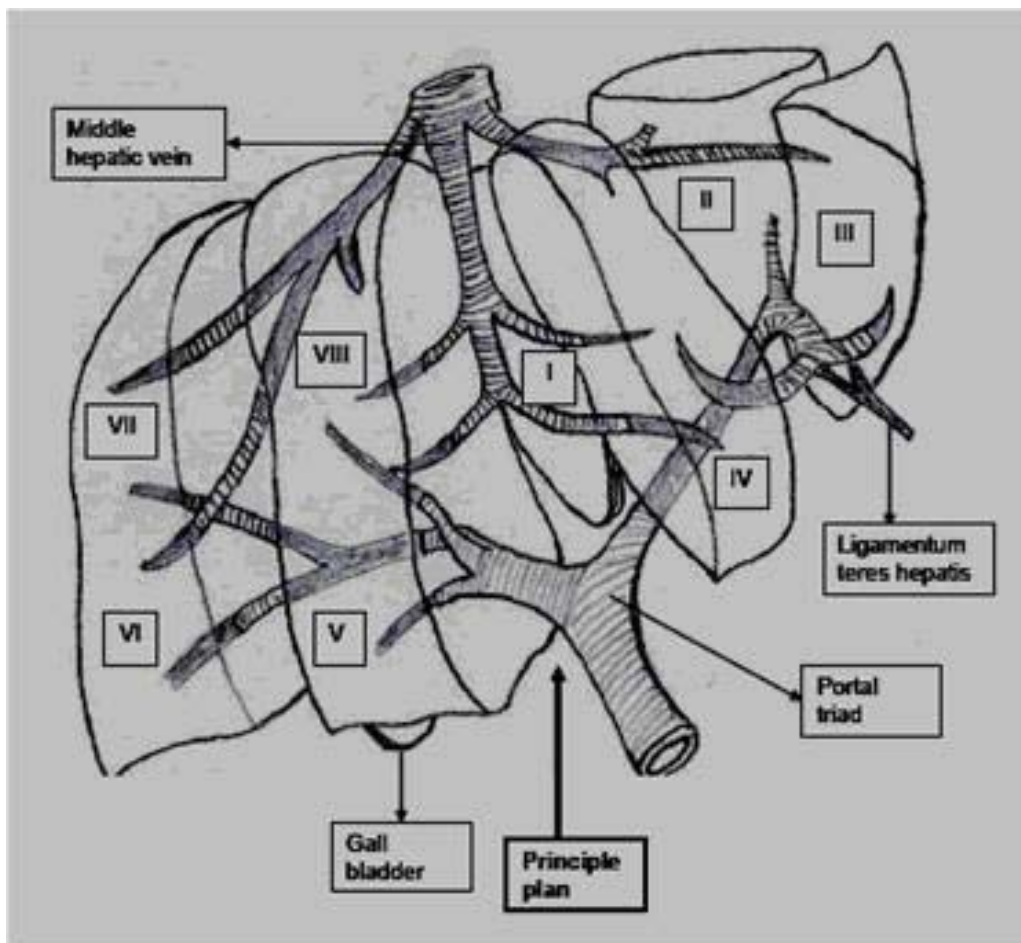
In adults, liver, as the largest solid organ in the body, accounts for about 2% of the total body weight with an average weight of 1350 grams. It is essentially located in the right hypochondria and shows close proximity of the anterior surface of the stomach, the left kidney, and the spleen. Its transverse diameter is approximately 21 to 23 cm and its thickness (at the midline of the right lobe) about 15 cm. The greatest antero-posterior diameter on the level of the upper pole of the right kidney is approximately 10 to 12 cm.

### **Peritoneal attachments (ligaments), superficial landmarks, and segmental anatomy**

The surgical anatomy of the liver has been traditionally described based on the regional proximities and superficial landmarks. The dome of the right hepatic lobe is in line with the midclavicular line approximately at the level of the fifth costa. The upper margin at the midline is on where the sternal body and the xiphoid cartilage conjoin. The upper margin of the left lobe is determined with a line from the xipho-sternal conjunction in lateral to the left side of the fifth costal cartilage 5 cm beyond the midline. The right margin of the liver fits with the arcus costarum.

Liver is fixed with the ligamentous structures of the parietal peritoneum extending toward hepatic surface. At the terminal point of both the right and left sides, two leaves of the coronary ligament conjoin in lateral forming the triangular ligaments. Posteriorly, the anterior leaf of the falciform ligament forms a T-shaped appearance together with the smaller

left triangular ligament and the larger right triangular ligament. The obliterated umbilical vein on the free margin of the falciform ligament is usually used to distinguish between the right and left ligaments. This distinction line is in fact on the left to the axis separating the liver into the right and left lobes. The line drawn from two fossae where posteriorly vena cava and anteriorly gall bladder are located is consistent with the true plane separating the liver into two surgical lobes (the right and left lobes). The angle of this plane is 35 degrees vertically, and 20 degrees sagittally. The line drawn between two fissures where ligamentum venosum and ligamentum teres are located separates the left lobe into the medial and lateral segments. The lobus quadratus forms the great portion of the medial segment of the left lobe. Due to its reciprocal blood supply and drainage, the lobus caudatus is a separate lobe not belonging either to the left or right side. Figure 1 shows lobar/ segmental anatomy of the liver.



**Figure 1.** Lobar/segmental (functional) anatomy of the liver (demonstrating segment I-VIII and principle plan between right and left lobes).

## **Hepatic blood supply**

Hepatic blood supply comes from two sources: hepatic artery (25%) and portal vein (75%). Blood flow emanating from the liver returns to the vena cava through the hepatic veins.

### **Hepatic arteries**

Arterial system: “Celiac artery→common hepatic artery→(gastroduodenal, right gastric) →proper hepatic artery→hepatic artery (right, left)”. In twenty-two percent of the people, the left hepatic artery arises from the left gastric artery, and there is only a single left hepatic artery in 50 % of the people. In 17 % of the people, the right hepatic artery arises from the superior mesenteric artery.

The right hepatic artery arises from the a. hepatica propria on the left to the ductus choledochus and proceeds towards the right as from behind this duct. In one half of the cases, cystic artery arises from the right hepatic artery, and there are some variations in the other half. The left hepatic artery supplies blood to the medial and lateral segments of the left lobe. This vessel is relatively short immediately subdividing into terminal branches. Because it progresses obliquely as from the lower surface superiorly and laterally, it makes possible to preserve the lateral segment of the left lobe, thus enabling nearly the total resection of the medial segment. As a rule, the artery is located just under the left hepatic duct. In most cases, the artery gives branches to the lateral and medial segments, thus following the branching of the portal vein and hepatic ducts in general. In 25 % of the cases, a large portion of arterial blood supply to the left lobe (medial segment) comes from the right hepatic artery.

The common hepatic artery is frequently a main branch arising from the celiac arterial stem in the upper side of pancreas. In approximately 3 % of the people, there is an abnormal main hepatic artery which arises from the superior mesenteric artery. It is related to the pancreatic head and neck; it sometimes passes through the head and then behind the portal vein, resulting in the whole blood supply of the duodenum coming from the superior mesenteric artery in such cases. Ligation of this vessel inadvertently not only causes hepatic ischemia and even necrosis, but also endangers duodenum. More frequently (27%), there may be seen variations in which the right or left hepatic artery arises from the superior mesenteric artery. Its trace is uncertain, but shows proximity to the pancreatic head and neck.

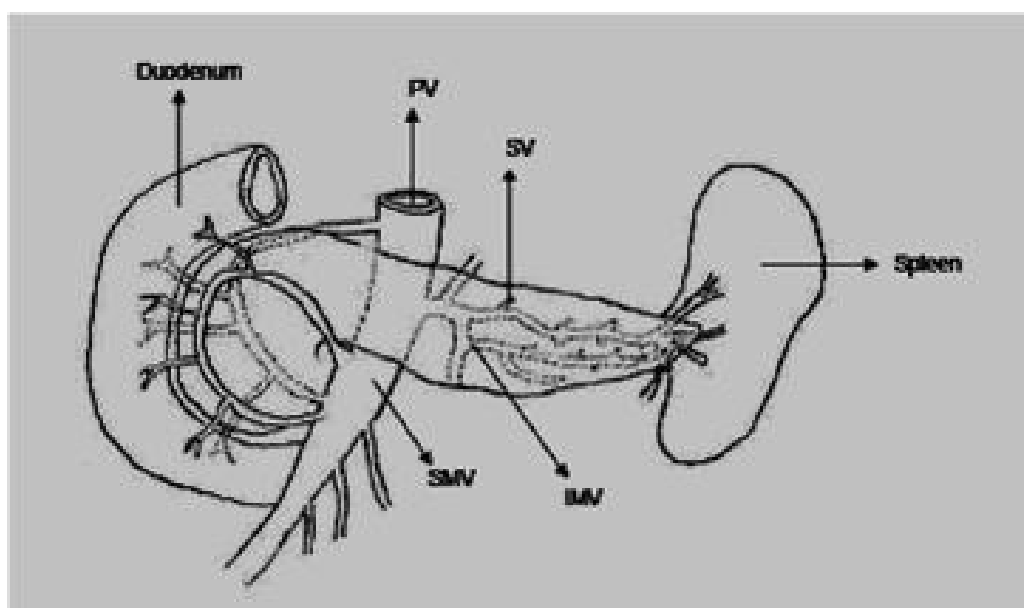
Historically, it was believed that hepatic arteries were end arteries having no anastomosis. Subsequent anatomic studies have demonstrated that there

are about 25 potential collateral arterial networks coming into liver. Following a hepatic artery ligation, a number of small collateral vessels begin to appear in the regions of caudate lobe and porta hepatis. Moreover, in 25% of the people, extrahepatic anastomoses have been shown to exist between the left and right hepatic arteries. All these anastomoses are of subcapsular and small diameter, of which many are in areas near lobus caudatus.

### Portal vein

Of approximately 7 to 8 cm length and containing no valves, the portal vein is formed by the union of superior, splenic and inferior mesenteric veins behind the pancreatic neck at the level of second lumbar vertebra (Figure 2). In one out of three cases, inferior mesenteric vein directly joins superior mesenteric vein. Additionally, there are a number of small venous structures joining the various parts of the portal vein from the surrounding organs (e.g., abdominal esophagus, stomach, and pancreas).

Portal vein is located in front of vena cava inferior and behind pancreas where hepatic artery and biliary duct are located its left and right sides, respectively. While descending obliquely toward the right side behind the initial part of the duodenum, the portal vein anteriorly intercrosses vena cava inferior and enters the free edge of the small omentum (hepatoduodenal ligament). In this region, the main biliary duct on its right is near the hepatic artery, which is on its behind left. This triple structure forms the anterior edge



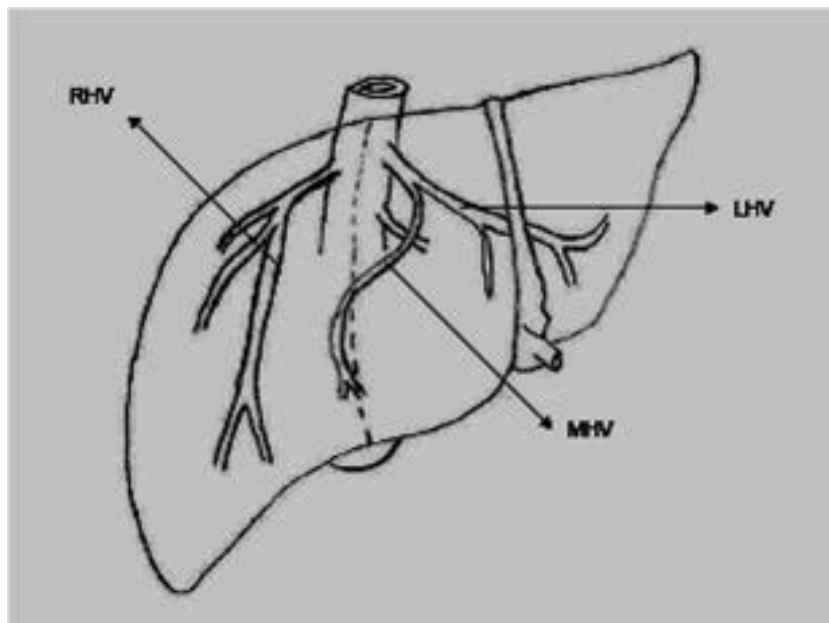
**Figure 2.** Extra-hepatic portal venous system (PV: Portal vein, SMV: Superior mesenteric vein, IMV: Inferior mesenteric vein, SV: Splenic vein).

of the epiploic fossa (Winslow) together with the peritoneal membrane. It travels posterior to common bile duct and hepatic artery in porta hepatis, gives off right and left portal branches in liver hilum. The longer left branch is morphologically less effective in terms of blood flow. The left portal vein has two portions: “transverse” portion progressing through the hilum, and “intrahepatic” portion progressing in the fissure of the umbilical vein.

The portal and superior mesenteric veins can be easily detached from the posterior surface of the pancreas in healthy cases. In very rare cases, the portal vein may run along in front of pancreas and duodenum (anterior replacing portal vein). Additionally, the portal vein may drain into superior vena cava or has a congenital stricture.

### Hepatic venous drainage

The venous return is principally achieved via the right, middle, and left hepatic veins. The posterior segment of the right lobe and a large portion of the upper surface of the anterior segment are drained via the right hepatic vein, the greatest one of these three veins. The middle and left hepatic veins either unite to join vena cava as a single truncus, or join vena cava at the separate but close points (triple confluence). The lower surface of the medial segment of the left lobe, and the lower surface of the anterior segment of the right lobe are drained via the middle hepatic vein. The upper part of the medial segment and the whole lateral segment of the left lobe are drained via the left hepatic vein (Figure 3).



**Figure 3.** Hepatic venous system (LHV: Left hepatic vein, MHV: Middle hepatic vein, RHV: Right hepatic vein).

The caudate lobe and some parts of the liver may show a direct drainage to vena cava. The caudate lobe is drained via two or more veins joining vena cava on the left and anteriorly. The posterior and lateral parts of the posterior segment of the right lobe are drained via few veins joining vena cava on the right posterolateral surface. The upper right vein may directly join vena cava, although it usually flows out to the upper side of the right hepatic vein. The upper left vein directly joins vena cava draining the area, which is confined by the left triangular ligament. In some instances, this vein may be ruptured while revealing the esophageal hiatus during the dissection of the left triangular ligament.

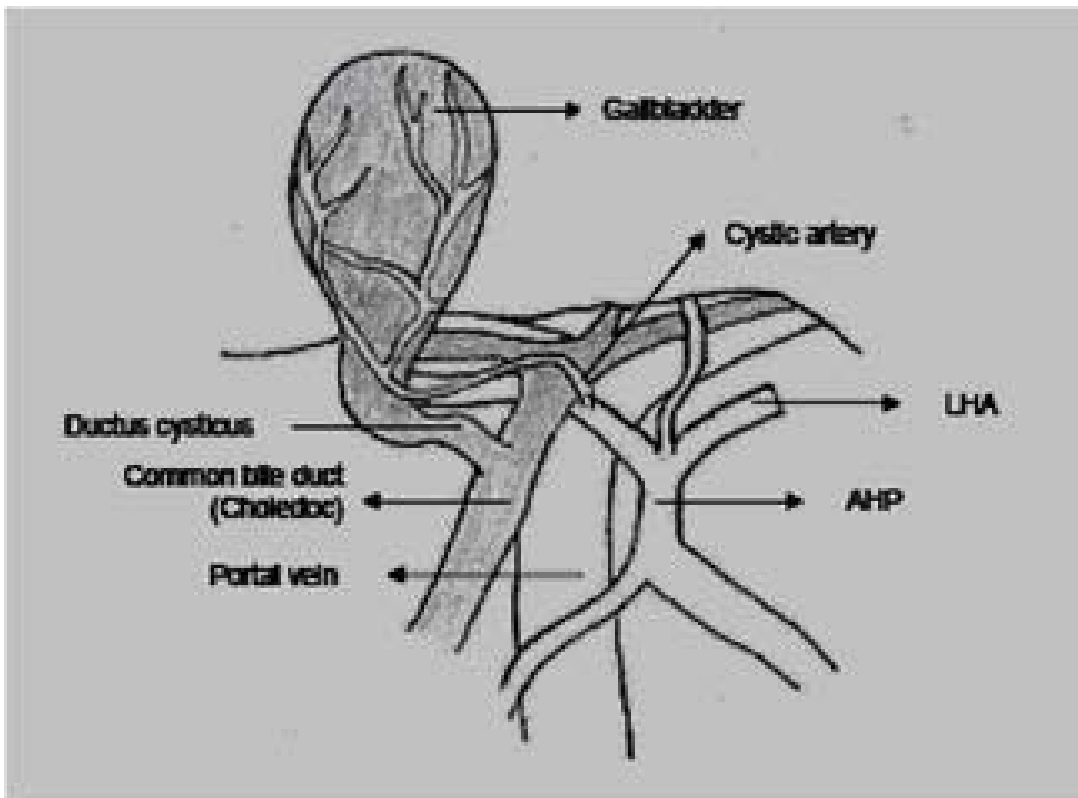
Hepatic venous system is valveless. Average blood flow is 1500 mL/min per 1.70 m<sup>2</sup> of body surface area. A number of anastomoses have been reported to exist between hepatic veins. In addition, it has been generally accepted that there are associations between the portal and hepatic venous systems. The respective associations are between the afferent venules of the portal system and the sublobular hepatic veins. When performed an injection into the hepatic veins only, the segmental distribution of the drainage can be obviously seen. However, such anatomic distribution is not in parallel with the segmental designation of the portal system. Two systems coalesce with each other such that when both are injected, no lobar or segmental planes can be seen.

### **Trans-hepatic biliary drainage**

Intrahepatic biliary network closely follows the hepatic arterial and portal vessels. Unlike arterial system, there is less evidence on the presence of functional anastomosis between the right and left lobes, except the conjunction of the right and left hepatic channels at porta hepatis. When performed an injection, there appears no association between the biliary channels of the anterior and posterior segments of the right lobe through the segmental fissure.

With a length of approximately 9 mm, the right hepatic channel consists of the union of anterior and posterior segmental channels near porta hepatis. The lateral segment of the left lobe is drained via two segmental channels. The caudate lobe is drained in a different manner, in which there may be seen a drainage to both right and left hepatic channel systems.

The right and left lobar channels unite to form the right and left hepatic channels. The latter unite to form the choledochal duct. The length of choledochal duct varies (2 to 7 cm), but usually follows a uniform course. The choledochal duct comes off the conjunction of the common hepatic channel and the cystic channel. It progresses on the free edge of the small omentum passing behind duodenum to open up to the Vater's ampulla. Figure 4 shows relationships between choledoc and hepatic artery/portal vein in hepatoduodenal ligament.



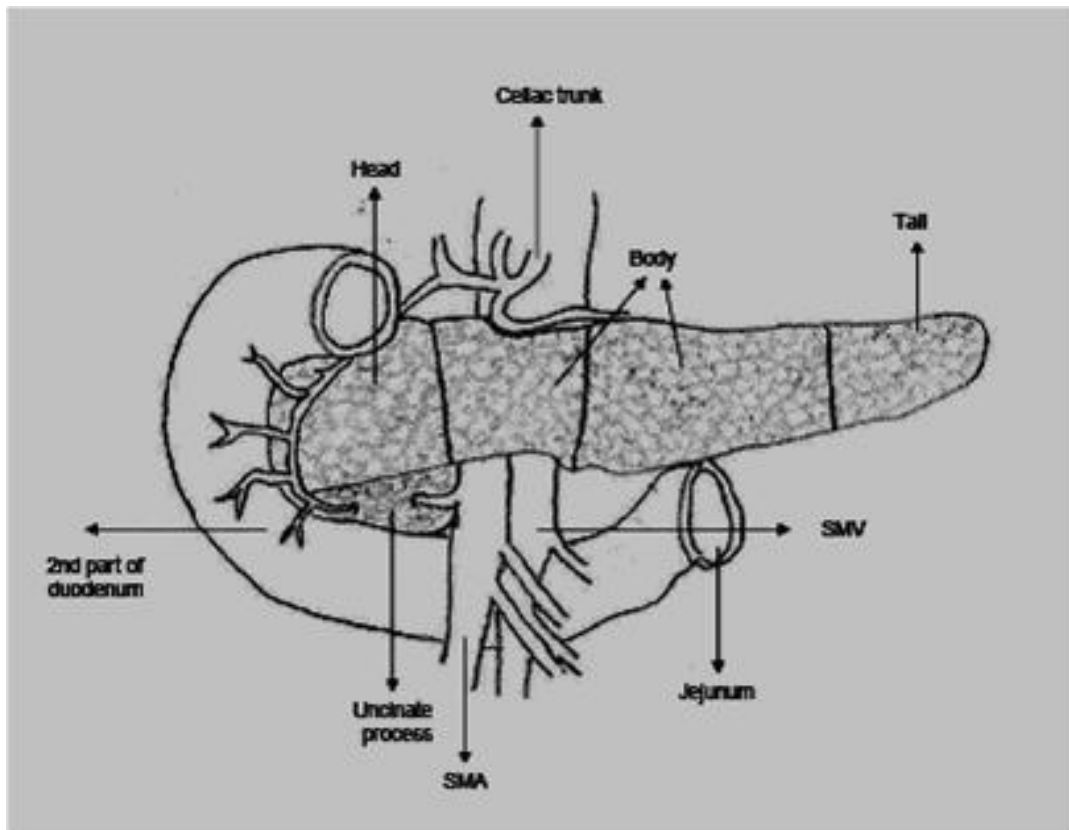
**Figure 4.** The relationships between choledoc and hepatic artery/portal vein in hepatoduodenal ligament (LHA: Left hepatic artery, AHP: Arteria hepatica propria).

## **Surgical anatomy of the pancreas (50-61, 63)**

Pancreas is a solid organ that is transversely located between duodenum on the right and spleen on the left in the retroperitoneal region. It is associated with omental bursa superiorly, transverse mesocolon anteriorly, and large omental pouch inferiorly.

### **Parts of the pancreas**

Pancreas consists of head, uncinate process, neck, body, and tail (Figure 5). The anterior surface of the head is adjacent to pylorus and colon. The anterior pancreaticoduodenal arcade is parallel to the duodenal curvature and associated with the pancreatic surface. The posterior surface of the pancreatic head is associated with the right renal hilus and medial edge, the right renal vessels and inferior vena cava, the right crus of the diaphragm, the posterior pancreaticoduodenal arcade, and the right gonadal vein. The distal part of the common bile duct (choledoc) is less frequently (15%) located behind the pancreatic head, and more frequently (85%) is sunk in the pancreatic body partially or completely.



**Figure 5.** Parts of the pancreas (SMV: Superior mesenteric vein, SMA: Superior mesenteric artery).

A projection from the pancreatic head extends toward below and slightly to the left to form the uncinata process. The uncinata process passes anteriorly to the inferior vena cava between the portal vein and superior mesenteric vessels. On the sagittal plane, the uncinata process remains between aorta and superior mesenteric artery where it shows proximity with duodenum superiorly and the left renal vein inferiorly. An uncinata process may not exist or circumscribe the superior mesenteric vessels completely.

The pancreatic neck has a length of approximately 2 cm. It is anteriorly concealed by pylorus to a limited extent, and extends toward to the right until the point where the anterior-superior pancreaticoduodenal artery comes off the gastroduodenal artery. The left edge of the neck is unclear. Behind the neck, the portal vein is formed by the union of superior mesenteric and splenic veins.

The anterior surface of the pancreatic body is covered by the double membrane of the peritoneum of omental bursa, separating the stomach from the pancreas. The body is associated with the transverse mesocolon. Arteria colica media comes off from the bottom of the pancreas and progresses

between two leaves of the mesocolon. Small pancreatic vessels open up to the splenic vein. These vessels should be ligated to preserve the splenic vein and the spleen during pancreatectomy.

The pancreatic cauda (tail) is relatively mobile. Its end reaches the splenic hilus. It is located between two leaves of the splenorenal ligament together with the beginning of the splenic vein, and the splenic artery. Outer leaf of this ligament is the posterior leaf of the gastrosplenic ligament, thus being avascular.

## **Pancreatic ducts and related structures**

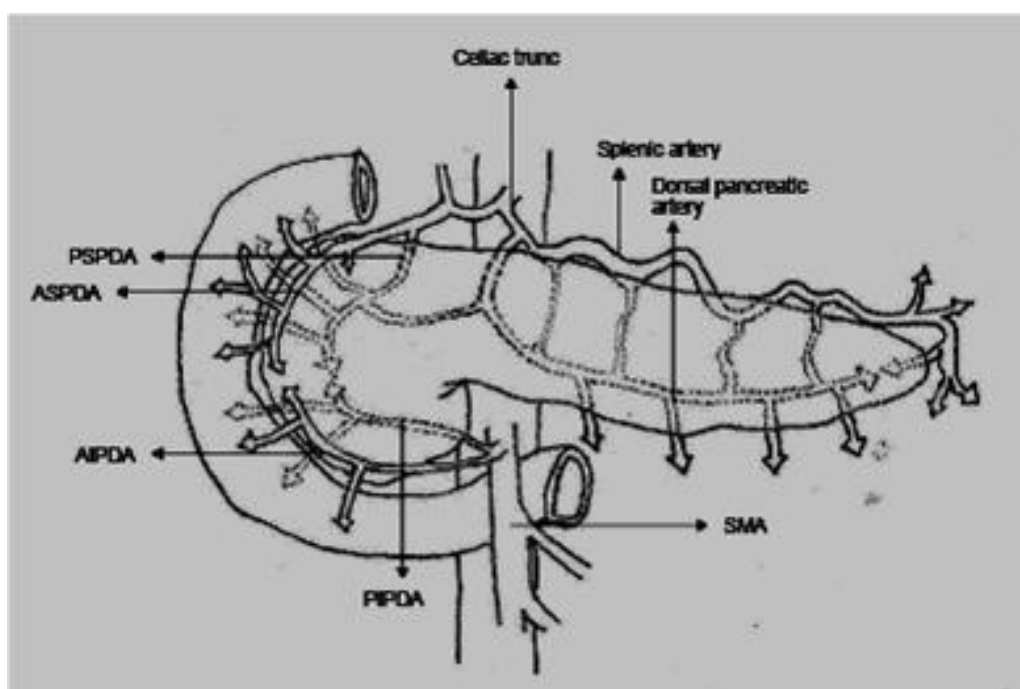
The main pancreatic duct (Wirsung) extends from the middle of the upper and lower edges and slight posteriorly along the pancreatic body and tail. The main pancreatic duct and the accessory duct (Santorini) are located in front of the major pancreatic vessels. In the pancreatic body and tail, fifteen to twenty short ductules open up to the main duct. The main duct opens up into duodenum at the level of major papilla (mostly at the level of the second lumbar vertebra). The accessory pancreatic duct (Santorini) drains off the antero-superior part of the pancreatic head into either main pancreatic duct or the duodenum via the minor papilla. The major duodenal papilla is at the distance of 7 to 10 cm from pylorus on the posteromedial wall of the second part of the duodenum. Rarely, papilla may be in the third part of the duodenum. Vater's ampulla (ampulla) corresponds to an area of expansion of the main pancreaticobiliary duct below the conjunction of two ducts and adjacent to papilla. There may be no ampulla in one out of three cases.

The most common pancreatic duct variation is that the accessory pancreatic duct (Santorini) open up to the duodenum with the minor papilla. The minor duodenal papilla is located at about 2 cm above the major papilla and slight anteriorly. Unlike the major papilla, it has no characteristic mucosal folds denoting its place, and is smaller than the major papilla.

Currently, it is believed that various sphincters composed of smooth muscle fibers circumscribe the ampulla, the pancreatic duct, and the intramural part of the biliary duct. Considering its contribution to the anatomy of this region, the whole sphincter complex is called Boyden sphincter. The total length of this sphincter complex ranges from 6 mm to 30 mm.

## **Pancreatic arterial blood supply**

Pancreatic blood supply comes from both the celiac truncus and the superior mesenteric artery (Figure 6). The pancreatic head and duodenal concave surface is always supplied by two (anterior and posterior)



**Figure 6.** Arterial blood supply of the pancreas (ASPDA: Anterior superior pancreatico-duodenal artery, PSPDA: Posterior superior pancreatico-duodenal artery, AIPDA: Anterior inferior pancreatico-duodenal artery, PIPDA: Posterior inferior pancreatico-duodenal artery, SMA: Superior mesenteric artery).

pancreatico-duodenal arterial arcades (arcus). Also supplying the duodenal wall, this vascular arcade is the primary obstacle in completing pancreatectomy without duodenectomy.

Gastroduodenal artery is the first large branch of the main hepatic branch of the celiac truncus. It gives the right gastroepiploic artery at about 1 cm away from its beginning, and thereafter subdivides into the posterior and anterior superior pancreaticoduodenal arteries. The anterior superior pancreaticoduodenal artery is on the anterior surface of the pancreas; it gives eight to ten branches to the anterior duodenal surface, an additional branch to the proximal jejunum, and a number of branches to the pancreas. During the resection of the pancreas, duodenal branches may be sacrificed, but jejunal branches should be protected. This artery enters the pancreas, and then joins the anterior inferior pancreaticoduodenal artery coming from the superior mesenteric artery in the posterior surface. The anterior inferior pancreaticoduodenal artery arises from the superior mesenteric artery at or above the upper edge of the pancreatic neck.

The blood supply of the pancreatic tail comes from the left gastroepiploic artery or a splenic branch at the splenic hilus. It makes anastomoses with the large pancreatic artery branches and other pancreatic arteries. The pancreatic tail artery supplies the accessory splenic tissue when it is at the hilus. There are three major variations of arterial blood supply of distal pancreas. The most

common type of these is observed in about 50% of people in which dorsal pancreatic artery joins with transverse pancreatic artery inside of the pancreas.

The splenic artery progresses by giving folds on the anterior and posterior surfaces, and below and above the pancreatic tail. The first large branch is the dorsal pancreatic artery, and frequently opens up to the upper posterior arcade after giving the inferior pancreatic branch to the left side. The ligation of the splenic artery does not require splenectomy. However, the ligation of the splenic vein requires splenectomy.

As mentioned earlier, in approximately 3 % of the people, there is an abnormal main hepatic artery which arises from the superior mesenteric artery. This aberrant artery is related to the pancreatic head and neck; it sometimes passes through the head and then behind the portal vein, resulting in the whole blood supply of the duodenum coming from the superior mesenteric artery. Ligation of this vessel inadvertently not only causes hepatic ischemia and even necrosis, but also endangers duodenum.

### **Pancreatic venous drainage**

In general, the pancreatic veins are parallel with the arteries and located more superficially. Arteries and veins are behind the pancreatic ducts. These veins are drained by the portal vein, and the superior and inferior mesenteric veins.

### **Pancreatic lymphatic drainage**

Pancreatic lymphatic drainage is complex as with the arterial blood supply. The lymphatic flow is usually parallel with the arterial/venous systems, and there is no standardized classification system for the lymph nodes.

### **Pancreatic nerves**

Pancreas is innervated by the splanchnic and vagal nerves from the autonomic nervous system. These nerves usually follow the blood vessels. These autonomic nerves carry afferent (motor) fibers to the blood vessels and the pancreatic ducts and glands, and contain visceral efferent (pain) fibers whose distribution is not well known.

### **Pancreatic exploration**

Pancreas can be reached by separating the gastrohepatic or gastrocolic omentum. Generally, the whole pancreas can be well seen by performing a wide incision of the gastrocolic omentum.

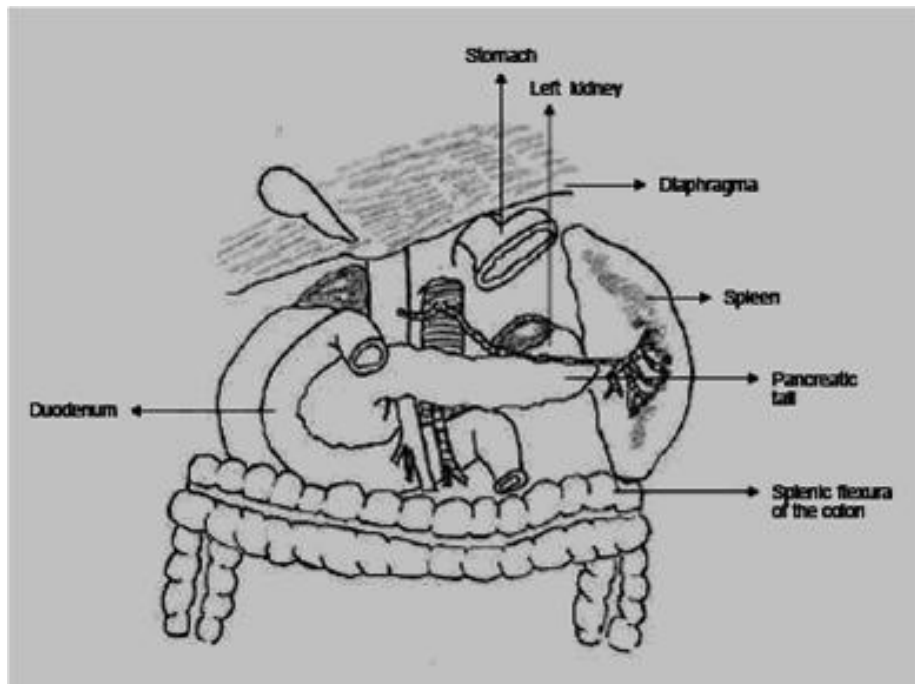
It is essential to liberalize duodenum with the Kocher's maneuver for the palpation of the pancreatic head. The mobilization of the duodenum is obtained by mobilizing the hepatic flexure and then incising the peritoneum from the lateral edge of the second part of the duodenum. Due to its close proximity with superior mesenteric artery and vein, evaluating and revealing the uncinata process is much more difficult.

## **Surgical anatomy of the spleen (50-61, 64)**

Spleen is solid organ located in the upper left abdominal quadrant, with a weight of about 100 to 150 g. Its lateral surface is in contact with diaphragm at the level of 9th to 11th costae, whereas it is in proximity to the large curvature of the stomach medially. The left kidney is behind the spleen. The lower pole of the spleen is in proximity to the splenic flexure of the colon.

### **Relation of the spleen to the pancreas**

The pancreatic tail is so close to the splenic hilus (Figure 7), and in 30% of the people, the pancreatic tail is in a direct contact to the spleen. In most of the cases having no direct contact, the distance between the pancreas and the splenic hilus is less than 1 cm. The close proximity of the pancreas with the splenic arteries and hilus is important for the splenectomy application.



**Figure 7.** Relations of the spleen to the pancreas, colon and left kidney.

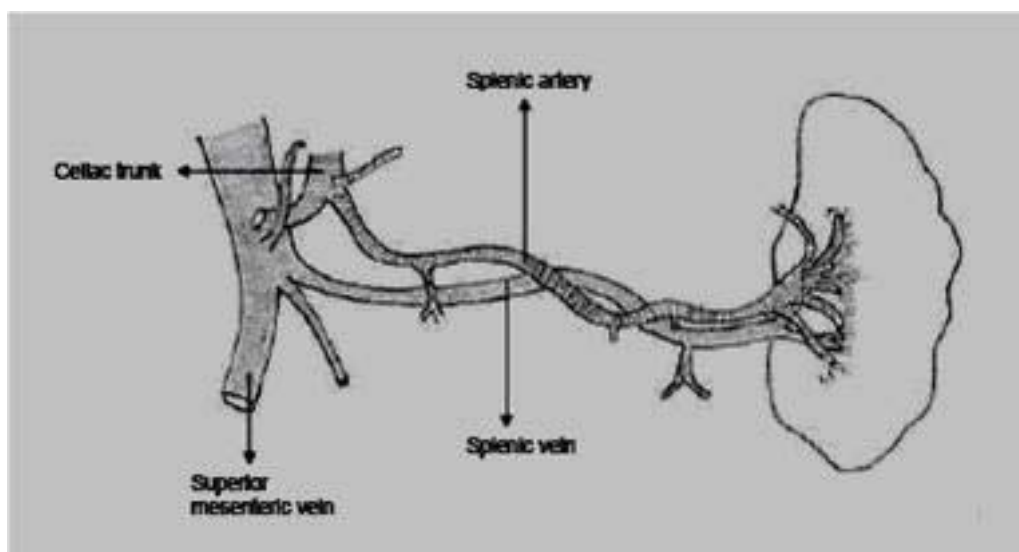
## Splenic ligaments

The peritoneal structures that form the splenic suspensory ligaments hold the spleen in the upper left abdominal quadrant. The peritoneum extends toward the spleen through the anterior and posterior gastric walls and forms the gastrosplenic ligament bearing the short gastric branches of the splenic vessels. Inferiorly, the gastrosplenic (gastrolial) ligament continues to the splenocolic ligament together with the larger omentum. Portion of the peritoneum in the posterior edge of the lateral surface extends to superior, lateral and inferior regions forming the splenophrenic, splenorenal and splenocolic ligaments, respectively.

## Splenic arteries

The splenic blood supply comes from the splenic artery, which arises from the celiac axis (Figure 8). Splenic artery gives several branches before entering the spleen. These include the short gastric arteries supplying the upper part of the large curvature of the stomach, and the left gastroepiploic arteries extending to more distant areas of the large curvature and to the large omentum. The main splenic artery usually gives branches at a distance of 3 to 4 cm before the hilus, although there may be branching at a distance of 1 to 12 cm from the hilus.

Due to the embryologic development of spleen, the formation of splenic arteries may occur in two types: marginal and diffuse types. In the marginal type, the main splenic artery gives short terminal branches near the hilus. In the diffuse type, the main splenic artery is short and spreads into the spleen with several long branches.



**Figure 8.** Splenic artery and vein.

## **Splenic veins**

The splenic vein consists of many branches leaving the spleen. The main branch usually follows a line from the left to the right, below and behind the splenic artery and behind the pancreatic tail and body. The splenic vein gathers the left gastroepiploic, few pancreatic and frequently inferior mesenteric veins, and combines with the superior mesenteric vein to form the portal vein behind the pancreatic neck. Short gastric veins discharge into the branches of the splenic vein or into the spleen directly.

## **Splenic lymphatics**

The splenic pulp contains no lymphatic vessels. The present lymphatics exist in the connective tissue and trabecules of the splenic capsule. The lymph nodules near the hilus receive lymphatic drainage from the stomach rather than spleen, and these lymphatics discharge to the lymph nodules accompanying the splenic artery.

## **Splenic nerves**

There is a nervous network extending from the celiac plexus near the splenic artery. Experiments carried on mammals revealed that spleen has only sympathetic innervation. In some species, stimulation of the splenic nerves leads to splenic contractions.

## **Surgical anatomy of kidneys & adrenals (50-61)**

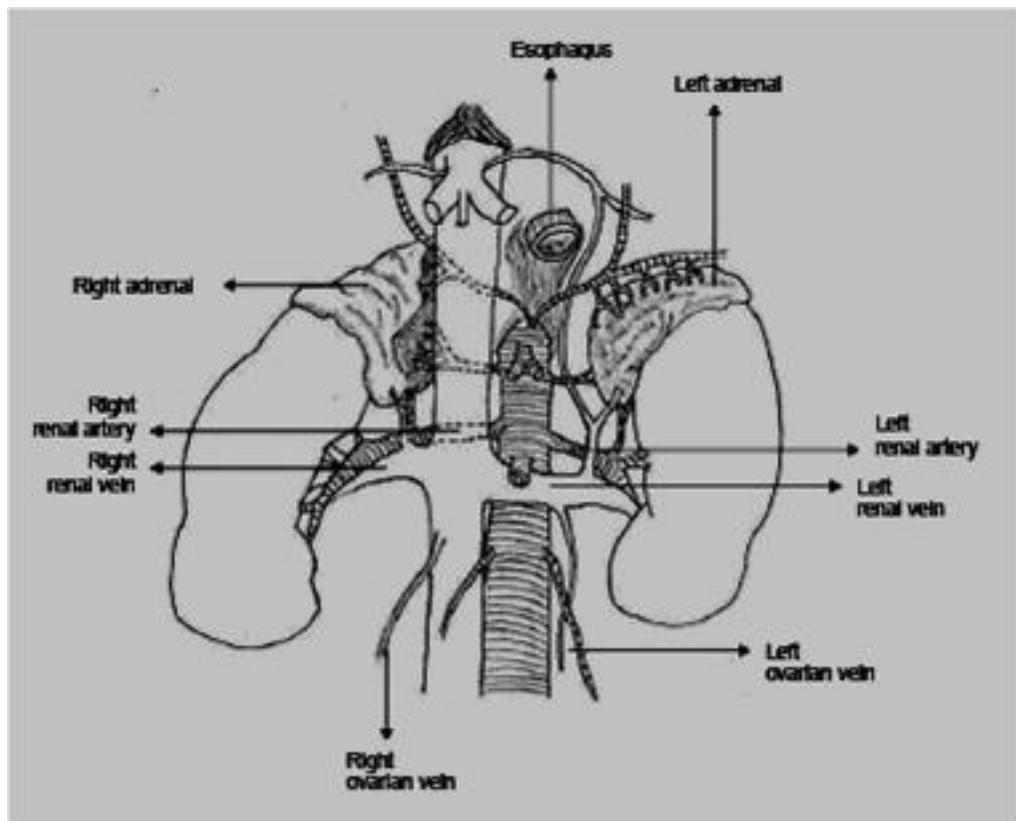
Kidneys are retroperitoneal organs located in both sides of the columna vertebralis. Both kidneys have two poles, one superior and the other inferior, two surfaces, namely anterolateral and posteromedial, and a hilus harboring neurovascular structures and pelvis renalis. Because the longitudinal axis of the kidneys is oblique, the superior and inferior poles are about 5 and 8 cm far from the midline, respectively. Due to the different relations to the liver and diaphragm, the right kidney is located at a lower level compared to the left one.

Kidneys are present in a bed composed of transverse fascia, arcuate ligaments, and perirenal fatty tissue in the subdiaphragmatic region. On the right, the anterior surface of the kidney is in close proximity to the right flexura coli and the descending duodenum. There is no peritoneum in these areas. On the left, there is a similar relation between the pancreatic tail and the descending colon.

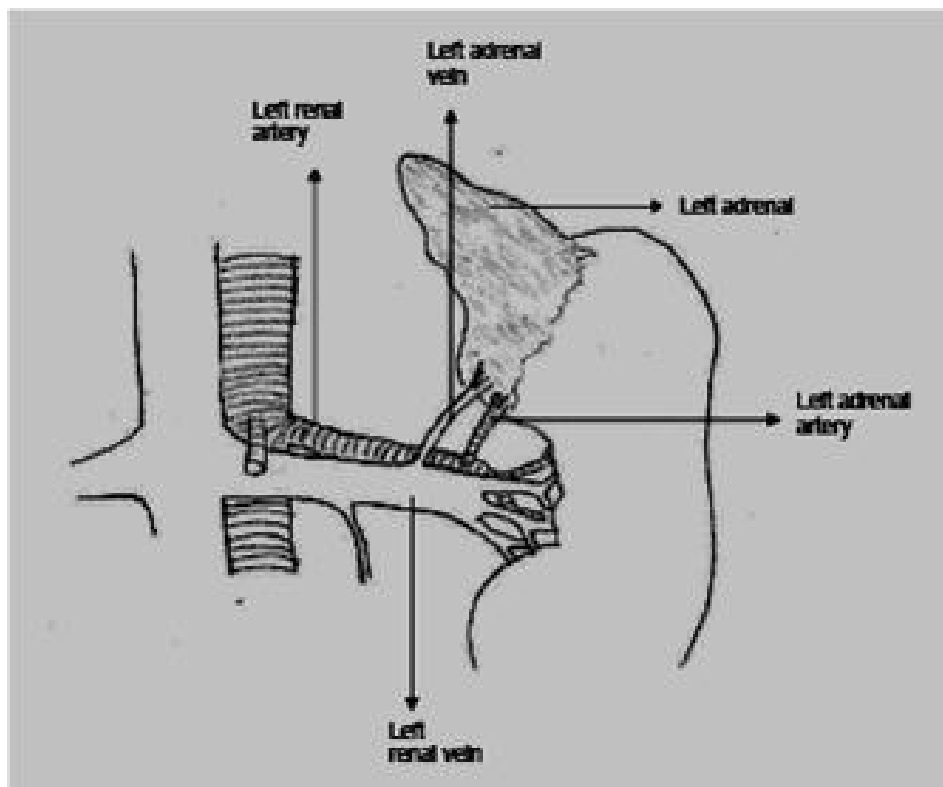
The renal fascial ligaments (renal= perirenal= Gerota's fascia) are originated from the retroperitoneal connective tissue and surround the kidney on the anterior and posterior surfaces.

Approximately 65% of the people, there is a single renal artery. Those arteries called renal accessory or aberrant arteries and usually progressing toward superior or inferior poles are extra or auxiliary arteries being the single arteries supplying their respective segments. After leaving the kidney, the renal vein follows the renal artery and opens up to the inferior vena cava (Figure 9).

Adrenal glands are endocrine organs that are located just over the superior renal poles, with a weight of approximately 3 to 5 g and a size of 5x2x1 cm. The right adrenal gland is in a close proximity to vena cava. The left adrenal gland is present between aorta and the anteromedial edges of the left kidney. Both glands are in yellow and more solid than perirenal fatty tissue. On the cross-section of a gland, the outer section is composed of yellowish-colored cortex, whereas the inner section is composed of red-brownish medulla. The adrenal glands are located over the compartment formed by the renal fascia; their positions are maintained by the vessels and fibrous ligands. The adrenal glands are highly rich in arterial blood supply. Arterial blood supply is



**Figure 9.** Renal artery and vein.



**Figure 10.** Left adrenal artery and vein.

provided by a. phrenica inferior superiorly, aorta centrally, and the branches of a. renalis inferiorly. Whereas the left adrenal vein frequently opens up to the left renal vein or vena cava inferior (Figure 10), many small veins originated from the right adrenal gland directly open to v. cava inferior.

## Acknowledgement

I would like to acknowledge Bugra Destan, M.D., from the Department of Cardiovascular Surgery for his appreciated contributions in providing figure drawings.

## References

1. Griffiths CT, Parker LM, Fuller AF Jr. Role of cytoreductive surgical treatment in the management of advanced ovarian cancer. *Cancer Treat Rep* 1979; 63: 235-240.
2. Wakabayashi MT, Lin PS, Hakim AA. The role of cytoreductive/debulking surgery in ovarian cancer. *J Natl Compr Canc Netw* 2008; 6: 803-10.
3. Ozols RF, Bundy BN, Greer BE, Fowler JM, Clarke-Pearson D, Burger RA, et al. Phase III trial of carboplatin and paclitaxel compared with cisplatin and

- paclitaxel in patients with optimally resected stage III ovarian cancer: a Gynecology Oncology Group study. *J Clin Oncol* 2003; 21: 3194-3200.
4. Aletti G, Dowdy SC, Gostout BS, Jones MB, Stanhope RC, Wilson TO, et al. Aggressive surgical effort and improved survival in advanced-stage ovarian cancer. *Obstet Gynecol* 2006; 107: 77-85.
  5. Chi DS, Franklin CC, Levine D, Akselrod F, Sabbatini P, Jarnigan WR, et al. Improved optimal cytoreduction rates for stages IIIC and IV epithelial ovarian, fallopian tube, and primary peritoneal cancer: a change in surgical approach. *Gynecol Oncol* 2004; 94: 650-4.
  6. Guidozi F, Jaqualine HS, Ball BS. Extensive primary cytoreductive surgery for advanced ovarian cancer. *Gynecol Oncol* 1994; 53: 326-330.
  7. Bristow RE, Tomacruz RS, Armstrong DK, Trimble EL, Montz FJ. Survival effect of maximal cytoreductive surgery for advanced ovarian carcinoma during the platinum era: a meta-analysis. *J Clin Oncol* 2002; 20: 1248-59.
  8. Eisenkop SM, Spirtos NM, Friedman RL, et al. Relative influences of tumor volume before surgery and the cytoreductive outcome on survival for patients with advanced ovarian cancer: a prospective study. *Gynecol Oncol* 2003; 90: 390-6.
  9. Scarabelli C, Gallo A, Franceschi S et al. Primary cytoreductive surgery with rectosigmoid colon resection for patients with advanced epithelial ovarian carcinoma. *Cancer* 2000; 88: 389-397.
  10. Chen LM, Leuchter RS, Lagasse LD, Karlan BY. Splenectomy and surgical cytoreduction for ovarian cancer. *Gynecol Oncol* 2000; 77: 362-368.
  11. van der Burg ME. Advanced ovarian cancer. *Curr Treat Options Oncol* 2001; 2: 109-18.
  12. Lygidakis NJ, Bhagat AD, Vrachnos P, Grigorakos L. Multiorgan resection for advanced abdominal malignancies--is it feasible? *Hepatogastroenterology* 2007; 54: 1353-8.
  13. Montz FJ, Schlaerth JB, Berek JS. Resection of diaphragmatic peritoneum and muscle: role in cytoreductive surgery for ovarian cancer. *Gynecol Oncol* 1989; 35: 338-40.
  14. Cliby W, Dowdy S, Feitoza SS, et al. Diaphragm resection for ovarian cancer: technique and short-term complications. *Gynecol Oncol* 2004; 94: 655-60.
  15. Gemignani ML, Chi DS, Gurin CC, et al. Splenectomy in recurrent epithelial ovarian cancer. *Gynecol Oncol* 1999; 72: 407-10.
  16. Eisenkop SM, Spirtos NM, Lin WC. Splenectomy in the context of primary cytoreductive operations for advanced epithelial ovarian cancer. *Gynecol Oncol* 2006; 100: 344-8.
  17. Magtibay PM, Adams PB, Silverman MB, Cha SS, Podratz KC. Splenectomy as part of cytoreductive surgery in ovarian cancer. *Gynecol Oncol* 2006; 102: 369-74.
  18. Mancini N, Bellati F, Muzii L, Calcagno M, Alon SA, Pernice M, et al. Splenectomy during secondary cytoreduction for ovarian cancer disease recurrence: surgical and survival data. *Ann Surg Oncol* 2006; 13: 1717-23.

19. Eisenkop SM, Spirtos NM, Lin WCM. Splenectomy in the context of primary cytoreductive operations for advanced epithelial ovarian cancer. *Gynecol Oncol* 2006; 100: 344-348.
20. Nicklin JL, Copeland RV, Lewandowski GS, Vaccanello L, Havenar LP. Splenectomy as part of cytoreductive surgery for ovarian carcinoma. *Gynecol Oncol* 1995; 58: 244-247.
21. Ayhan A, Al RA, Baykal C, Demirtas E, Ayhan A, Yuce K. The influence of splenic metastases on survival in FIGO stage IIIc epithelial ovarian cancer. *Int J Gynecol Cancer* 2004; 14: 51-6.
22. Chi DS, Abu-Rustum NR, Sonoda Y, et al. Laparoscopic and hand-assisted laparoscopic splenectomy for recurrent and persistent ovarian cancer. *Gynecol Oncol* 2006; 101: 224-227.
23. Andelson MD. Ultrasonic surgical aspirator in cytoreduction of splenic metastases to avoid splenectomy. *J Reprod Med* 1992; 37: 917-20.
24. Yildirim Y, Sancı M. The feasibility and morbidity of distal pancreatectomy in extensive cytoreductive surgery for advanced epithelial ovarian cancer. *Arch Gynecol Obstet* 2005; 272: 31-34.
25. Kehoe SM, Eisenhauer EL, Abu-Rustum NR, et al. Incidence and management of pancreatic leaks after splenectomy with distal pancreatectomy performed during primary cytoreductive surgery for advanced ovarian, peritoneal and fallopian tube cancer. *Gynecol Oncol* 2009; 112: 496-500.
26. Merideth MA, Cliby WA, Keeney GL, Lesnick TG, Nagorney DM, Podratz KC. Hepatic resection for metachronous metastases from ovarian carcinoma. *Gynecol Oncol* 2003; 89: 16-21.
27. Bosquet JG, Merideth MA, Podratz KC, Nagorney DM. Hepatic resection for metachronous metastases from ovarian carcinoma. *HPB* 2006; 8: 93-96.
28. Yoon SS, Jarnagin WR, Fong Y, DeMatteo RP, Barakat RR, Blumgart LH, Chi DS. Resection of recurrent ovarian or fallopian tube carcinoma involving the liver. *Gynecol Oncol* 2003; 91: 383-388.
29. Abood G, Bowen M, Potkul R, Aranha G, Shoup M. Hepatic resection for recurrent metastatic ovarian cancer. *Am J Surg* 2008; 195: 370-373.
30. Lim MC, Kang S, Lee KS, Han SS, Park SJ, Seo SS, Park SY. The clinical significance of hepatic parenchymal metastasis in patients with primary epithelial ovarian cancer. *Gynecol Oncol* 2009; 112: 28-34.
31. Baron M, Hamou L, Laberge S, Callonnec F, Tielmans A, Dessogne P. Metastatic spread of gynaecological neoplasms to the adrenal gland: case reports with a review of the literature. *Eur J Gynaecol Oncol* 2008; 29: 523-6.
32. Einat S, Amir S, Silvia M, Moshe I. Successful laparoscopic removal of a solitary adrenal metastasis from ovarian carcinoma: a case report. *Gynecol Oncol* 2002; 85: 201-203.
33. Cortes J, Uriz A, Terrasa J, et al. Ovarian cancer metastatic to the kidney: case report. *Eur J Gynaecol Oncol* 1986; 7: 206-209.
34. Berek JS, Hacker NF, Lagasse LD, et al. Survival of patients following secondary cytoreductive surgery in ovarian cancer. *Obstet Gynecol* 1983; 61:189-193.
35. Segna RA, Dottino PR, Mandeli JP, et al. Secondary cytoreduction for ovarian cancer following cisplatin therapy. *J Clin Oncol* 1993; 11: 434-439.

36. Gadducci A, Iacconi P, Cosio S, et al. Complete salvage surgical cytoreduction improves further survival of patients with late recurrent ovarian cancer. *Gynecol Oncol* 2000; 79: 344-349.
37. Eisenkop SM, Friedman RL, Spirtos NM. The role of secondary cytoreductive surgery in the treatment of patients with recurrent epithelial ovarian carcinoma. *Cancer* 2000; 88: 144-153.
38. Gungor M, Ortac F, Arvas M, et al. The role of secondary cytoreductive surgery for recurrent ovarian cancer. *Gynecol Oncol* 2005; 97: 74-79.
39. Pfisterer J, Harter P, Canzler U, et al. The role of surgery in recurrent ovarian cancer. *Int J Gynecol Cancer* 2005; 15: 195-198.
40. Ayhan A, Gultekin M, Taskiran C, et al. The role of secondary cytoreduction in the treatment of ovarian cancer: Hacettepe University experience. *Am J Obstet Gynecol* 2006; 194: 49-56.
41. Benedetti Panici P, De Vivo A, Bellati F, Manzi N, Perniola G, Basile S, Muzii L, Angioli R. Secondary cytoreductive surgery in patients with platinum-sensitive recurrent ovarian cancer. *Ann Surg Oncol* 2007; 14: 1136-42.
42. Salani R, Santillan A, Zahurak ML, Giuntoli RL 2nd, Gardner GJ, Armstrong DK, Bristow RE. Secondary cytoreductive surgery for localized, recurrent epithelial ovarian cancer: analysis of prognostic factors and survival outcome. *Cancer* 2007;109: 685-91.
43. Tebes SJ, Sayer RA, Palmer JM, Tebes CC, Martino MA, Hoffman MS. Cytoreductive surgery for patients with recurrent epithelial ovarian carcinoma. *Gynecol Oncol* 2007; 106: 482-7.
44. Bae J, Lim MC, Choi JH, Song YJ, Lee KS, Kang S, Seo SS, Park SY. Prognostic factors of secondary cytoreductive surgery for patients with recurrent epithelial ovarian cancer. *J Gynecol Oncol* 2009; 20: 101-6.
45. Cheng X, Jiang R, Li ZT, Tang J, Cai SM, Zhang ZY, Tian WJ, Zang RY. The role of secondary cytoreductive surgery for recurrent mucinous epithelial ovarian cancer (mEOC). *Eur J Surg Oncol* 2009 May 12. [Epub ahead of print].
46. Barlin JN, Ueda SM, Bristow RE. Cytoreductive surgery for advanced and recurrent endometrial cancer: a review of the literature. *Womens Health (Lond Engl)* 2009; 5: 403-11.
47. Suh-Burgmann E, Powell CB. Cytoreductive surgery for gynecologic malignancies-new standards of care. *Surg Oncol Clin N Am* 2007; 16: 667-82.
48. Lambrou NC, Gómez-Marín O, Mirhashemi R, Beach H, Salom E, Almeida-Parra Z, Peñalver M. Optimal surgical cytoreduction in patients with Stage III and Stage IV endometrial carcinoma: a study of morbidity and survival. *Gynecol Oncol* 2004; 93: 653-8.
49. Giuntoli RL 2nd, Garrett-Mayer E, Bristow RE, Gostout BS. Secondary cytoreduction in the management of recurrent uterine leiomyosarcoma. *Gynecol Oncol* 2007;106: 82-8
50. Schwartz's principles of surgery. Eighth edition, Editors: F. Charles Brunicaudi, Dana K. Andersen, Timothy R. Billiar, David L. Dunn, Raphael E. Pollock. McGraw-Hill Companies, Inc., USA, 2005.

51. Anatomical complications in general surgery. Editor: John E. Skandalakis. Pages 108-113 (liver anatomy), 149-153 (pancreas anatomy), 179-181 (spleen anatomy), 189-191 (adrenal anatomy). McGraw-Hill Book Co., Singapore, 1986.
52. Vascular anatomy in abdominal surgery. Editor: Jean-Piere Van Damme, pages 83-113 (practical considerations). Thieme Medical Publishers, Inc., New York, 1990.
53. A colour atlas of surgical anatomy of the abdomen. Roy Yorke Calne. Wolfe Medical Publications, London, 1988.
54. Surgical anatomy of the abdomen. J.F.Lange and G.J.Kleinrensink (Eds), Elsevier, The Netherlands, 2002.
55. Diagnostic and surgical imaging anatomy: chest, abdomen, pelvis. International Edition Michael P. Federle, Melissa L. Rosado De Christenson, Paula J. Woodward, Gerald F. Abbott, Akram M. Shaaban (Editor). Lippincott Williams & Wilkins, 2006.
56. Color atlas of human anatomy: internal organs. 5th edition. H. Fritsch, W. Kuehnel. Georg Thieme Verlag., Stuttgart, Germany, 2008.
57. Sabiston textbook of surgery: The biological basis of modern practicsurgical practice. 18<sup>th</sup> edition. Ed: Courtney M Townsend. Saunders, 2007.
58. Mastery of surgery. 1st edition. Editors: Robert J. Baker, Lloyd M. Nyhus. Little Brown and Company, Boston, 1984.
59. Shackelford's surgery of the alimentary tract. Fourth edition. Editor: George D Zuidema. W.B. Saunders Company, Philadelphia, 1996.
60. Zollinger's atlas of surgical operations. Seventh edition. Editor: Robert M Zollinger. McGraw-Hill, Inc., USA, 1993.
61. Blood supply and anatomy of upper abdominal organs. Michels NA. Lippincott, Philadelphia, 1955.
62. Nakamura S, Tsuzuki T. Surgical anatomy of the hepatic veins and the inferior vena cava. Surg Gynecol Obstet 1981; 132: 43.
63. White TT. Surgical anatomy of the pancreas. In LC Carey (Ed). The Pancreas. Mosby, St. Louis, 1973.
64. Michels NA. The variational anatomy of the spleen and splenic artery. Am J Anat 1942; 70: 21.